



IMAGING BIOMARKERS IN GEOGRAPHIC ATROPHY (GA)

INDICATION

IZERVAY[™] (avacincaptad pegol intravitreal solution) is indicated for the treatment of geographic atrophy (GA) secondary to age-related macular degeneration (AMD)

IMPORTANT SAFETY INFORMATION

CONTRAINDICATIONS

IZERVAY is contraindicated in patients with ocular or periocular infections and in patients with active intraocular inflammation.

WARNINGS AND PRECAUTIONS

Endophthalmitis and Retinal Detachments

- Intravitreal injections, including those with IZERVAY, may be associated with endophthalmitis and retinal detachments. Proper aseptic injection technique must always be used when administering IZERVAY in order to minimize the risk of endophthalmitis. Patients should be instructed to report any symptoms suggestive of endophthalmitis or retinal detachment without delay and should be managed appropriately.

Please see Important Safety Information continued throughout and [click here](#) for full Prescribing Information.

EARLY DETECTION MEANS EARLY PROTECTION

1.5 million patients in the US are living with GA, but 75% of patients living with GA are undiagnosed^{1,2}

Multimodal imaging is critical in the early detection and monitoring of GA progression. Employing a combination of imaging modalities yields a more nuanced understanding of pathology and progression, revealing early signs of GA. This guide illustrates the presentation of GA biomarkers on imaging modalities you may have in your practice.

LOOK FOR THE FOLLOWING BIOMARKERS INDICATIVE OF GA

Color fundus photography (CFP)

- 1 Drusen
- 2 Sharply demarcated lesion, typically circular with increased choroidal visibility

Fundus autofluorescence (FAF)

- 3 Hypofluorescence with a sharply demarcated border
- 4 Hyperfluorescence surrounding atrophic lesion (indicative of lipofuscin accumulation and prognostic of GA progression)³

Optical coherence tomography (OCT)

- 5 Choroidal hypertransmission (increased light transmission into the choroid where the RPE is attenuated or absent)⁴
- 6 Loss of retinal pigmented epithelium (RPE), photoreceptor (PR), choriocapillaris layers

IMPORTANT SAFETY INFORMATION (CONT'D)

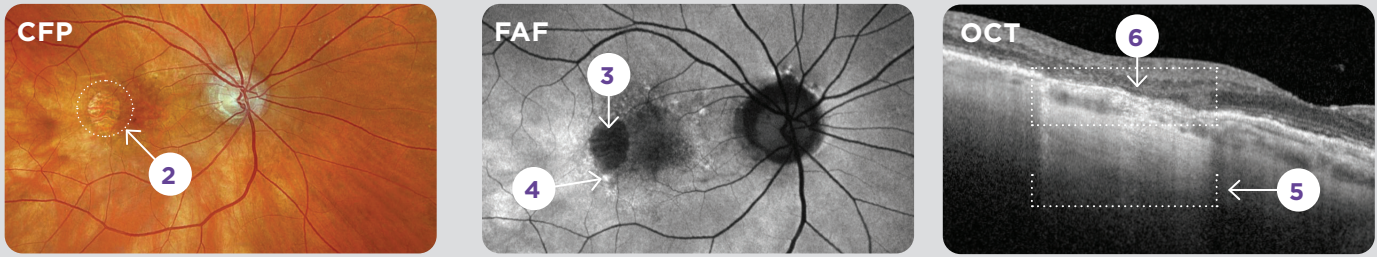
WARNINGS AND PRECAUTIONS (CONT'D)

Neovascular AMD

- In clinical trials, use of IZERVAY was associated with increased rates of neovascular (wet) AMD or choroidal neovascularization (7% when administered monthly and 4% in the sham group) by Month 12. Patients receiving IZERVAY should be monitored for signs of neovascular AMD.

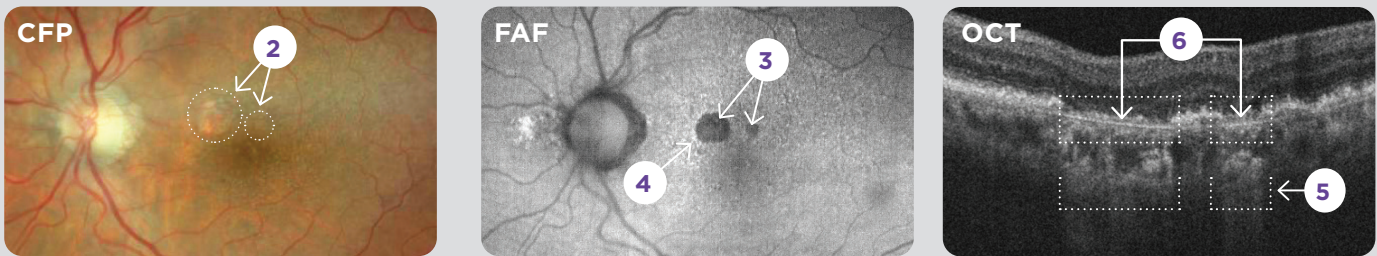
Please see Important Safety Information continued throughout and [click here](#) for full Prescribing Information.

Patient 1: Moderate GA with nonfoveal lesion



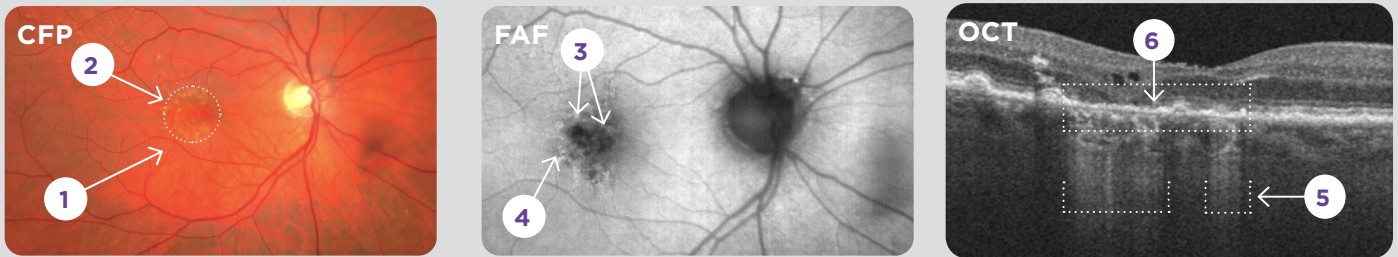
Images courtesy of Dr Mohammad Rafieetary.

Patient 2: Early GA with multifocal nonfoveal lesions



Data on file.

Patient 3: Early GA with multifocal foveal lesions and extensive intermediate drusen



Images courtesy of Dr Mark Dunbar.

Progression indicators include: irregularly shaped lesions, multifocality, large lesions at baseline, banded or diffuse hyperfluorescent patterns, bilateral lesions.^{3,5,6}

IMPORTANT SAFETY INFORMATION (CONT'D)

WARNINGS AND PRECAUTIONS (CONT'D)

Increase in Intraocular Pressure

- Transient increases in intraocular pressure (IOP) may occur after any intravitreal injection, including with IZERVAY. Perfusion of the optic nerve head should be monitored following the injection and managed appropriately.

Please see Important Safety Information continued throughout and [click here](#) for full Prescribing Information.



EVERY MONTH MATTERS FOR YOUR PATIENTS WITH GA: ACT EARLY WITH IZERVAY



**IZERVAY slowed GA
growth by up to 35%
in just 12 months^{†7}**

Trial design: The safety and efficacy of IZERVAY were demonstrated in GATHER1 and GATHER2: 2 randomized, multi-center, double-masked, sham-controlled studies in patients with GA secondary to AMD. 292 patients were treated with IZERVAY 2 mg, and 332 patients received sham. The primary efficacy endpoint in both pivotal studies was the mean rate of GA growth (slope) from baseline to Month 12 over 3 timepoints: Baseline, Month 6, and Month 12. In each study, over a 12-month period, there was a statistically significant reduction of the rate of GA growth (0.10 mm/year; $p < 0.01$ in GATHER1 and 0.05 mm/year; $p < 0.01$ in GATHER2 with square root transformed data) in patients treated with IZERVAY compared to sham.⁷

⁷Reduction in GA rate of growth at 12 months (MMRM analysis):⁷

- GATHER1: 35% reduction with IZERVAY (n=67) vs sham (n=110); difference (95% CI) (mm²/year): 0.67 (0.21-1.13); $p < 0.01^{*†}$
- GATHER2: 18% reduction with IZERVAY (n=225) vs sham (n=222); difference (95% CI) (mm²/year): 0.38 (0.12-0.63); $p < 0.01^{*†}$

MMRM=mixed models for repeated measures.

*Non-transformed GA growth slope analysis.

†Percent difference is calculated by $100 \times (\text{difference}) / (\text{least squares mean from sham})$.

IMPORTANT SAFETY INFORMATION (CONT'D)

ADVERSE REACTIONS

Most common adverse reactions (incidence $\geq 5\%$) reported in patients receiving IZERVAY were conjunctival hemorrhage, increased IOP, blurred vision, and neovascular age-related macular degeneration.

Please see Important Safety Information continued throughout and [click here](#) for full Prescribing Information.



**Scan here to learn more
at [IZERVAYECP.com](https://www.izervayecp.com).**

REFERENCES:

1. Friedman DS, O'Colmain BJ, Muñoz B, et al. Prevalence of age-related macular degeneration in the United States. *Arch Ophthalmol*. 2004;122(4):564-572.
2. IQVIA Medical Claims (Dx) Data Jan'20-Dec'21: 24 Months. **3.** Fleckenstein M, Mitchell P, Freund KB, et al. The progression of geographic atrophy secondary to age-related macular degeneration. *Ophthalmology*. 2018;125(3):369-390. **4.** Karmel M. Hypertransmission defects predict GA formation. *EyeNet Magazine* (Feb 2022): 13-15. **5.** Domalpally A, Danis RP, White J, et al. Circularity index as a risk factor for progression of geographic atrophy. *Ophthalmology*. 2013;120(12):2666-2671. **6.** Shen LL, Sun M, Grossetta Nardini HK, Del Priore LV. Progression of unifocal versus multifocal geographic atrophy in age-related macular degeneration: a systematic review and meta-analysis. *Ophthalmol Retina*. 2020;4(9):899-910. **7.** IZERVAY™ (avacincaptad pegol intravitreal solution) Prescribing Information. IVERIC bio, Inc., Parsippany, NJ 07054.